

# DMV. Ph. BEGHIN

PLACE FRANCO-BELGE 12 6200 CHATELET

Telephone: 071 39 14 79

Fax:

Site internet:



Nom: ZERROUG, OHLLYOHLM

ID: 20171123-103908-1313

Age: 2Ans

Sexe: Femme

**Cardio-pédiatrique**

Date exam: 23/11/2017

Médecin réf.: DR WILLEM

Equipement utilisé: Mindray DC-8 EXP

Opérateur: Admin

**Commentaires:** CONTROLE CARDIAQUE

PAS DE SOUFFLE

PAS D ARYTHMIE

BON ETAT GENERAL

PAS DE FATIGABILITE

## Cardiologie - 1 / 5 Page

### Mesures 2D

#### Dimensions

##### AG/Ao (2D)

Diam AG: 1.97cm

Diam Ao: 2.36cm

AG/Ao: 0.83

#### Volume Ventricule

##### Cube(2D)

FC: 97Bpm

### Mesures Mode M

#### Volume Ventricule

##### Teichholz(M)

SIVd: 1.05cm

DIVGd: 2.88cm

PPVGd: 1.43cm

SIVs: 1.88cm

DIVGs: 1.64cm

PPVGs: 1.56cm

FC: 97Bpm

VTD(Teich): 31.61ml

VTS(Teich): 7.65ml

VES(Teich): 23.96ml

FE(Teich): 75.80%

DC (Teich): 2.324l/min

FR(Teich): 42.99%

### Mesures Doppler

#### Valve Mitrale

Vit pic E VM: 54.27cm/s

GPE VM: 1.18mmHg



Nom: ZERROUG, OHLLYOHLM  
 ID: 20171123-103908-1313 Age: 2Ans Sexe: Femme

**Cardio-pédiatrique**

Date exam: 23/11/2017 Médecin réf.: DR WILLEM

**Cardiologie - 2 / 5 Page**

Vit pic A VM: 34.17cm/s

GP A VM: 0.47mmHg

E/A VM: 1.59

Aorte

Valve aortique

Vmax VA: 102.51cm/s

GPmax VA: 4.20mmHg

Valve Pulmonaire

VP

Vmax VP: 152.76cm/s

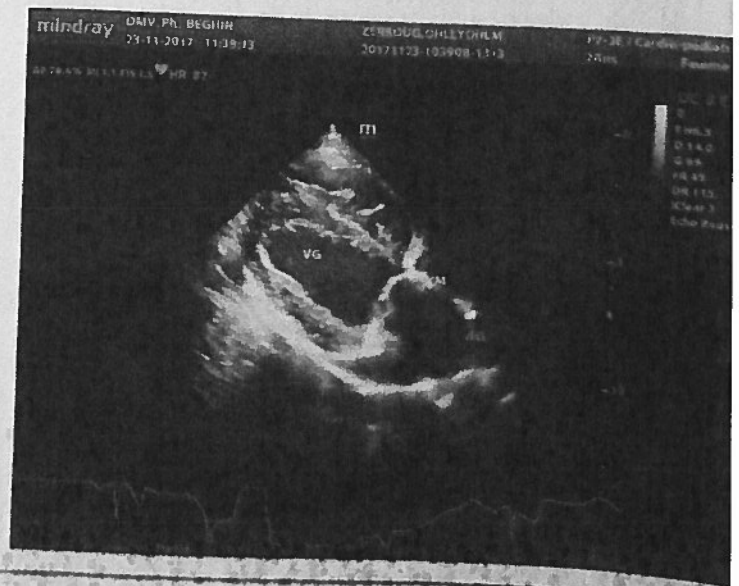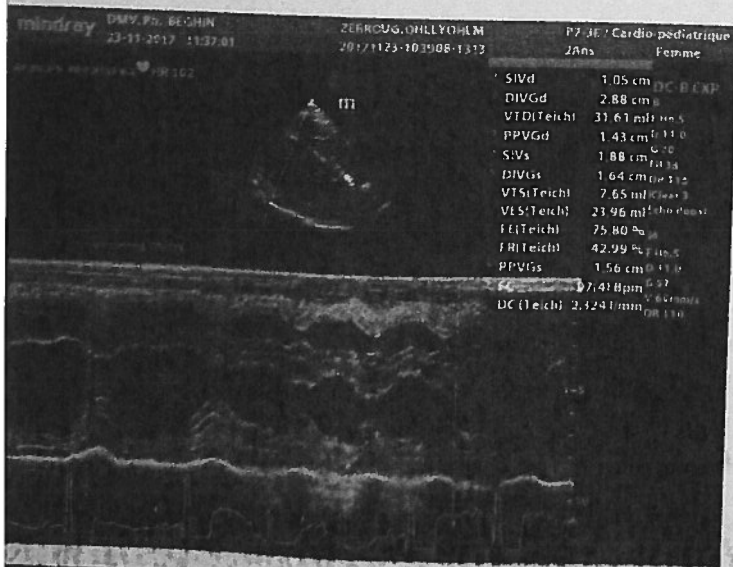GPmax VP: 9.33mmHg

lesures TDI

E/Ea VM

Vit pic E VM: 54.27cm/s

Image ultrason

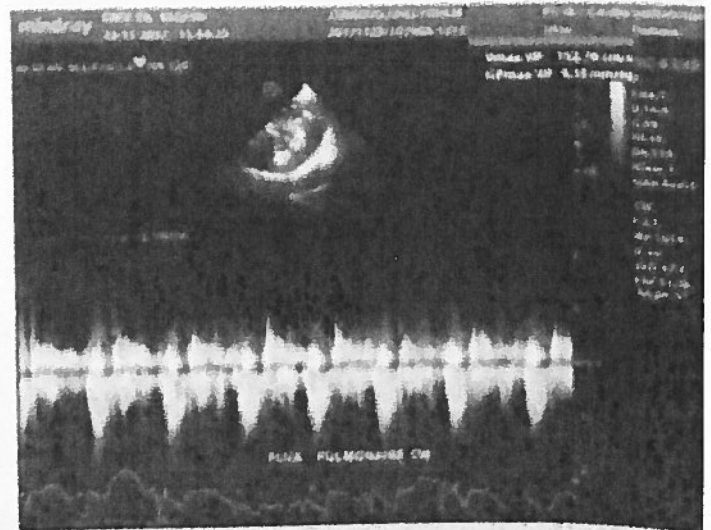
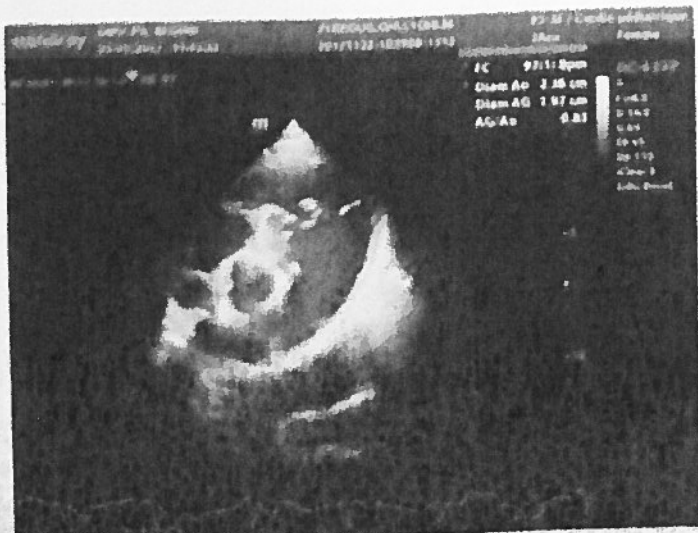
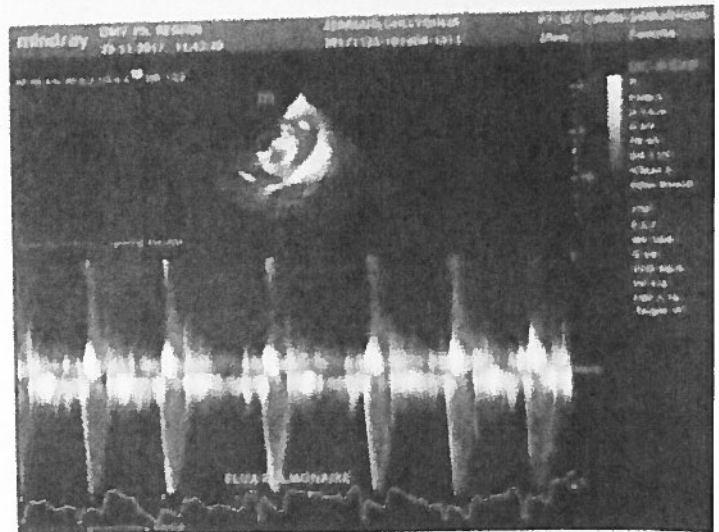
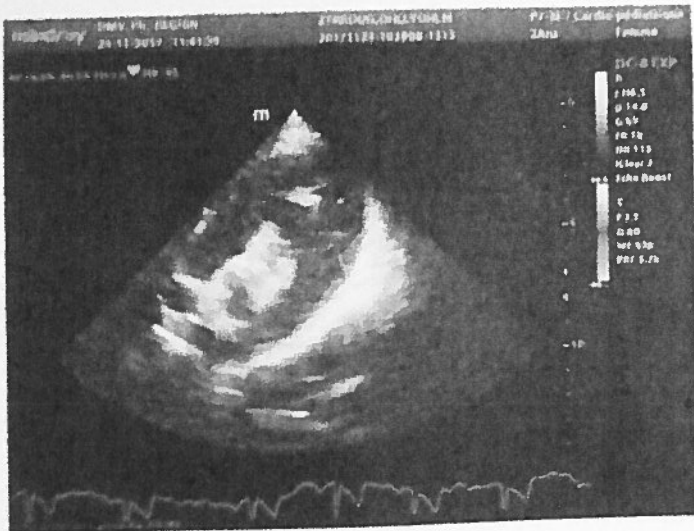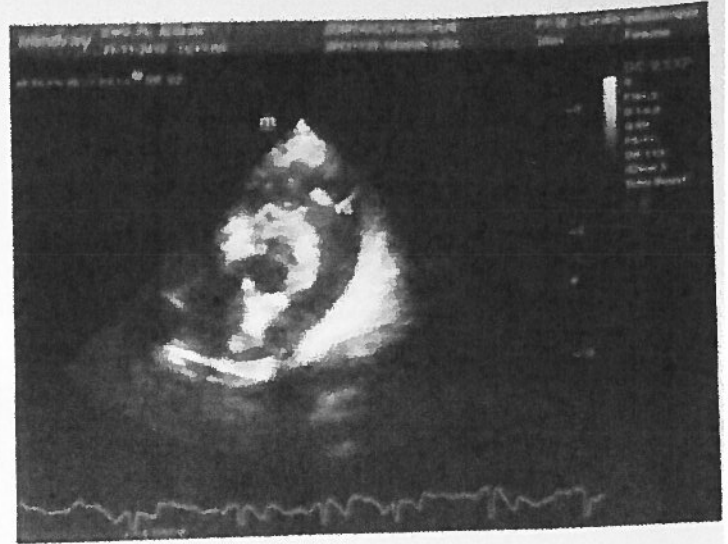

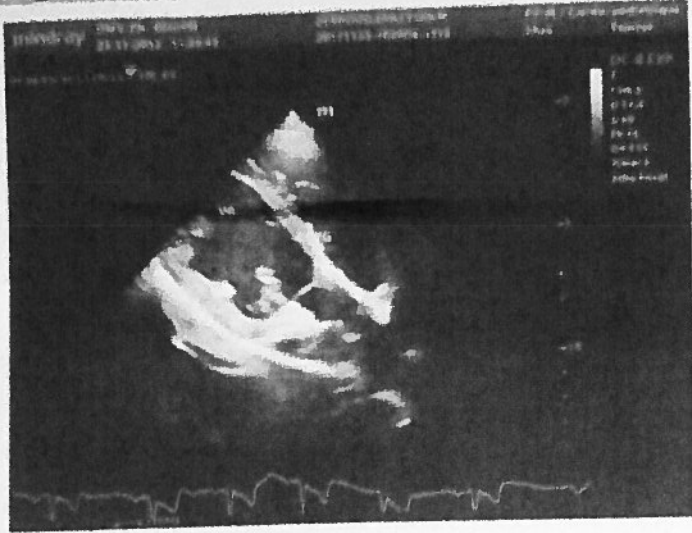


Nom: ZERROUG, OHLLYOHLM  
ID: 20171123-103908-1313 Age: 2 Ans Sexe: Femme  
Cardio-pédiatrique  
Date exam: 23/11/2017 Médecin réf.: DR WILLEM

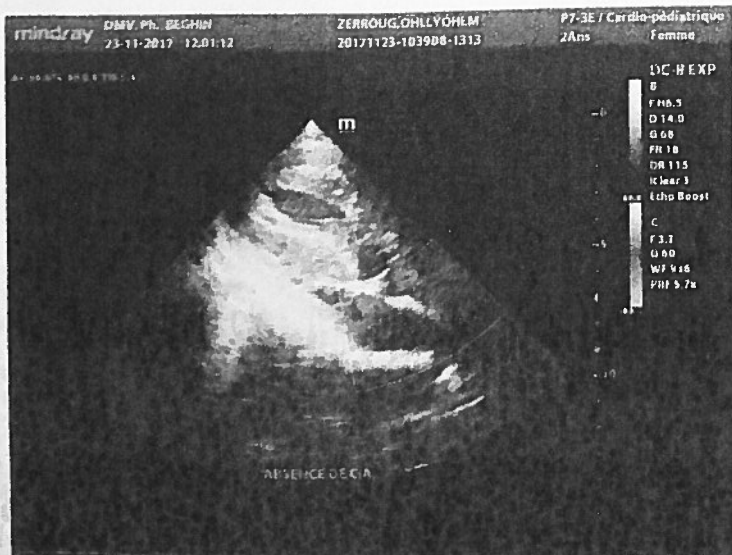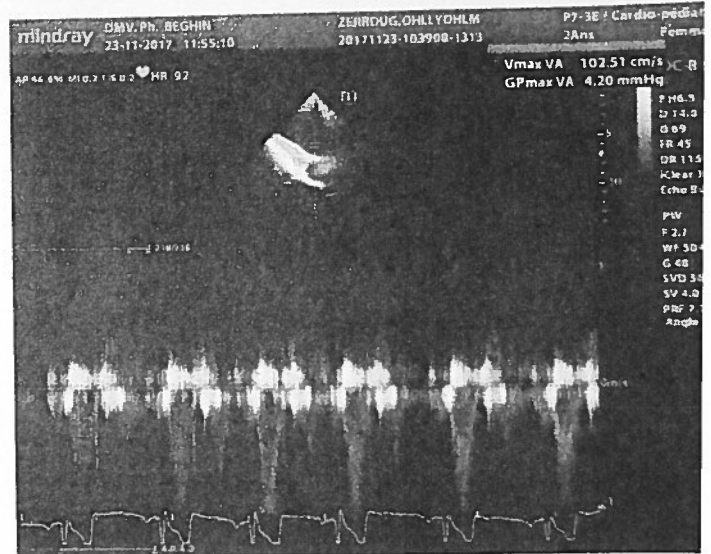
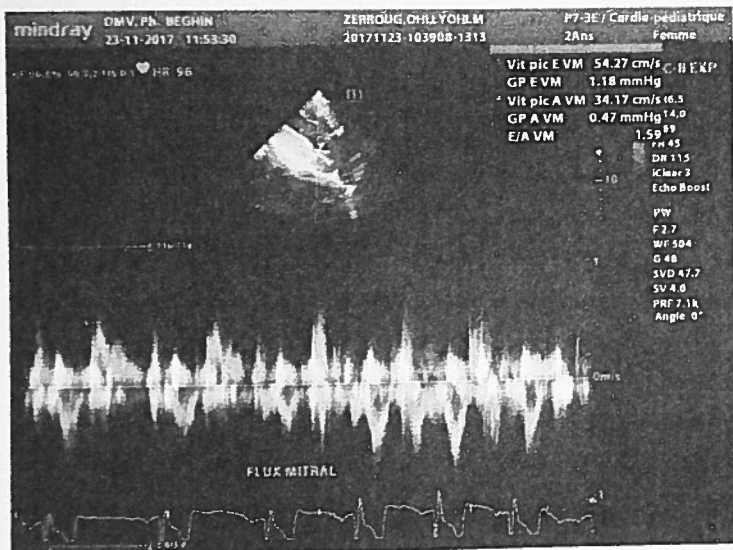
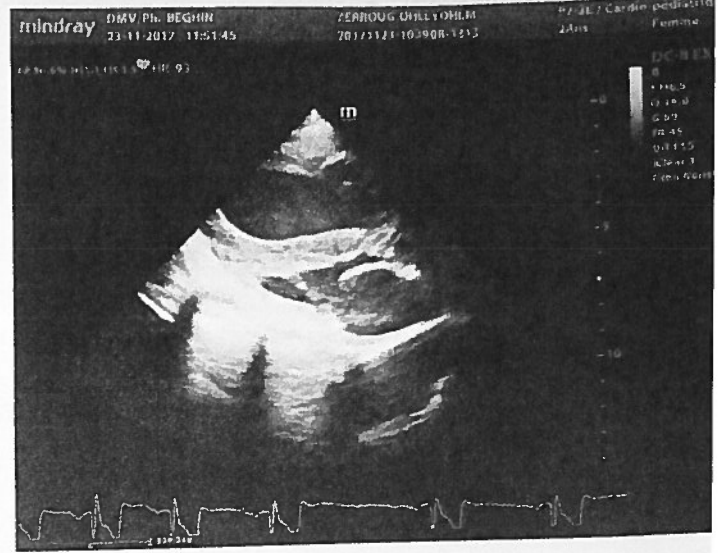
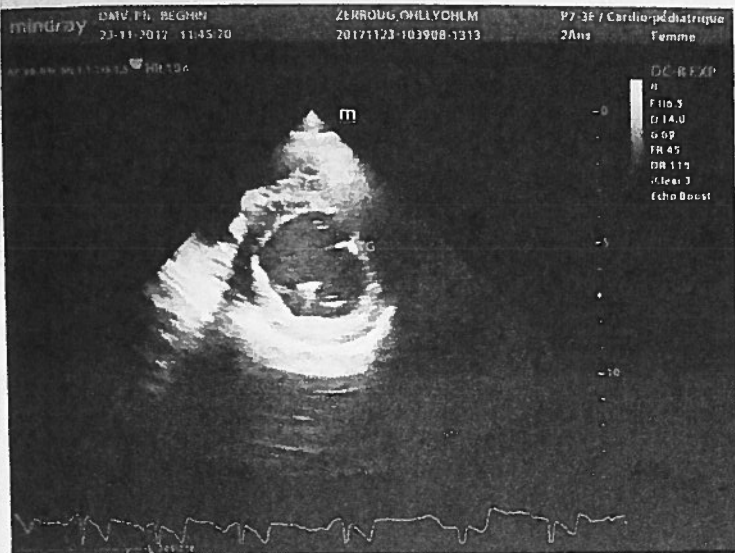
Cardiologie - 3 / 5 Page

Image ultrason



**Cardiologie - 4 / 5 Page**

**Image ultrason**





**Nom:** ZERROUG, OHLLYOHLM

**ID:** 20171123-103908-1313 **Age:** 2

**Cardio-pédiatrique**

**Date exam:** 23/11/2017 **Médecin**

**Card**

**Commentaires:** tres bon examen cardiaque  
pas de SSA pas de SP pas de CIA  
pas de bourrelet sous aortique dans la CCVG  
pas de dilatation du tronc pulmonaire  
les flux transvalvulaires sont normaux